

## Extraction Method of Abnormal Parts in Retinal Layers from Optical Coherence Tomography Image

Mohd Fadzil bin Abdul Kadir<sup>1</sup>, Ai Yamakawa<sup>2</sup>, Dai Kodama<sup>2</sup>, Shinji Tsuruoka<sup>3</sup>, Hiroharu Kawanaka<sup>2</sup>, Haruhiko Takase<sup>2</sup>, Yukitaka Uji<sup>4</sup>, Hisashi Matsubara<sup>4</sup>, Fumio Okuyama<sup>5</sup>

<sup>1</sup> Graduate School of Engineering, Mie University, Japan  
and University of Darul Iman Malaysia, Malaysia

<sup>2</sup> Graduate School of Engineering, Mie University, Japan

<sup>3</sup> Graduate School of Regional Innovation Studies, Mie University, Japan

<sup>4</sup> Graduate School of Medicine, Mie University, Japan

<sup>5</sup> Graduate School of Health Science, Suzuka University of Medical Science, Japan

**Abstract**— Optical Coherence Tomography (OCT) image is very useful to the diagnosis and the follow up evaluation of the response to treatment using either medication or surgery, and it is an emerging medical imaging technology for performing high resolution cross-sectional images. In ophthalmology, this technology can provide 3D images of retinal architecture, and it is useful for identifying, monitoring, quantitatively assessing of retinal disease. Evaluations of quantitative information on retinal architecture especially on the abnormal parts are importance to diagnosis the degree of abnormal and to consider a treatment approach. This research proposes a new extraction method for the abnormal regions of retina from 3D OCT images using the combination of digital image processing methods. Our research objectives are extracting the border line of abnormal parts of 3D OCT retinal images. This research uses 128 2D OCT images about one retina of a patient, which is specified the part of macular by an ophthalmologist. We can extract some border lines of abnormal parts in OCT retinal images by using image processing techniques.

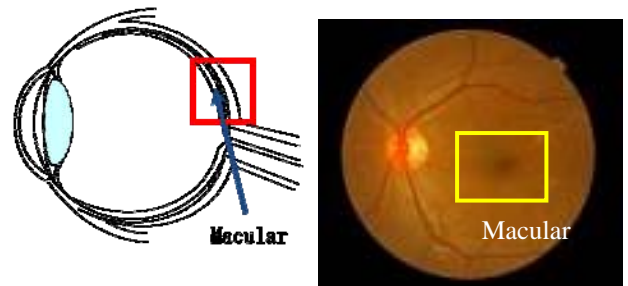
**Keywords**— Optical coherence tomography (OCT), image processing, image diagnosis system, retinal layer structure

### I. INTRODUCTION

Optical Coherence Tomography (OCT) image is very useful to the diagnosis and the follow up evaluation of the response to treatment using either medication or surgery, and it will be accepted widely as a new type of optical imaging that provides high-resolution, cross sectional images of tissues structure in situ and in real time (Fig. 1).

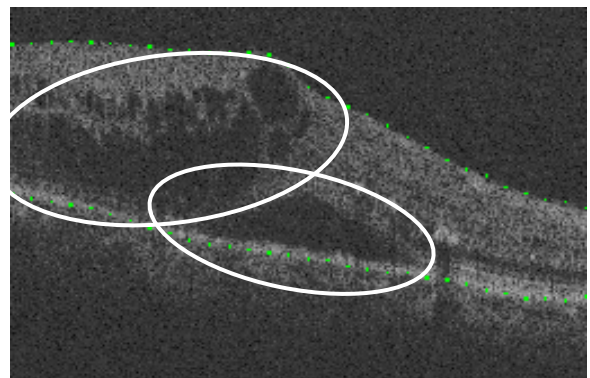
OCT imaging is similar to ultrasound, except it uses light instead of sound. With this technology, it is possible to perform imaging of internal structure of retina by measuring their optical reflections [1] [2]. Cross-sectional images are generated by scanning the optical beam in the transverse direction, thus yielding a 2-dimensional data set can be

displayed as a false-color or grayscale image [1]. The generated OCT image would measure the structural imaging of retina pathology at an intra-retinal level, and the needs of retinal diagnosis using OCT images have been growing [2][3]. Recently, dramatic advances in OCT technology provide OCT imaging with 3-dimensional (3D) information for eye ground images [4][5].



(a) Structure of an eye

(b) Eye ground image



(c) OCT image with abnormal parts (white circle)

Fig. 1 An example of OCT retinal image

In the previous researches, Yagi et al. [6] proposed the extraction method of thickness of ILM and RPE using morphological operations. However, the proposed method has the weakness that some extracted lines are disconnected for the input OCT image having some disappearance points. Yamakawa et al. [7] proposed a new extraction method by using one dimensional active net (ODAN) to improve the weakness, and the correct rate of extraction is increased.

Most ophthalmologists are interesting in the size and form of abnormal parts, however, the previous methods cannot extract the border line of the abnormal parts.

In this paper, we describe a new extraction method for the abnormal parts in retina from 3D OCT images using the combination of digital image processing methods. An OCT system can obtain a set of raster scan OCT images in a specified region for a macular. Our system employed the OCT images, and it could detect the border lines of the abnormal parts and could estimate the volume of abnormal parts automatically.

Medical doctors could diagnosis the degree of the abnormal part, and they could consider a treatment approach.

## II. PROPOSED BORDER LINE EXTRACTION METHOD

This research employs a set of 128 2D images “3D image” (512 x 480 pixels x 128 images, 16 bits/pixel, about 3mm x 3mm) about one retina of a drusen patient, which is specified the part of macular by an ophthalmologist. Recently, ophthalmologist uses a computer system to gather the information from digital images.

Some OCT images have some abnormal parts (Fig.2).

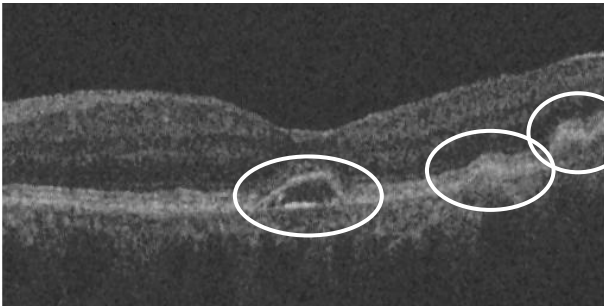


Fig.2 An OCT image with abnormal parts (white circle)

The mechanisms of the abnormal parts are some reasons such as drusen and angiogenesis. Some ophthalmologists make the diagnosis of a disease using measuring the volume and surface form of each abnormal part. We are considering the method of extracting the border line of the abnormal part from 2D OCT image to display the surface of the ab-

normal part. We will construct the computer aided diagnosis system with some doctor interventions.

Our extraction procedure of abnormal parts is shown in Fig. 3.

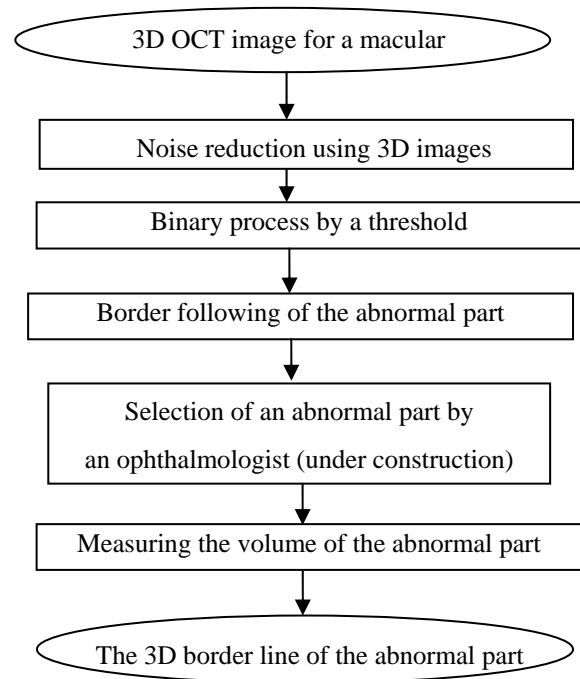


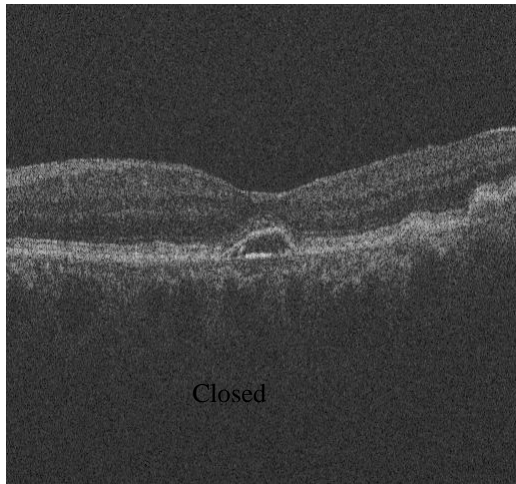
Fig. 3 Extraction procedure of abnormal parts

This extraction procedure is designed to extract the abnormal parts specified by an ophthalmologist, and this system will aid for the diagnosis of a disease in retina layer. In designing this algorithm, the processing time also should be considered.

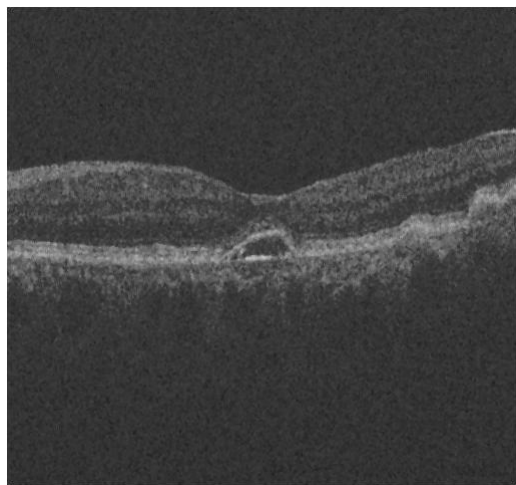
## III. EXTRACTED IMAGES

Fig. 4 shows the examples of input OCT images, smoothed images, binary images and border line images.

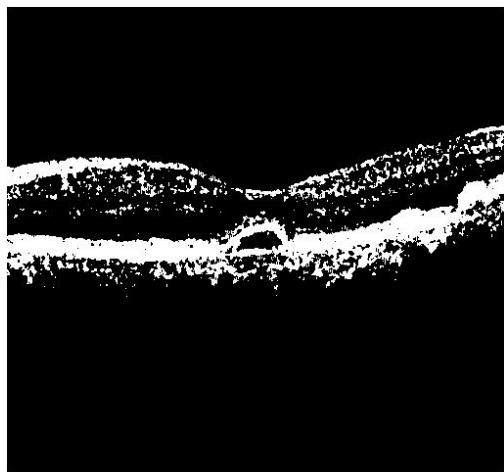
The retinal OCT image of Fig. 4 (a) overlaps three abnormal parts with some noises such as small speckles. We use 2D medial filter to remove the noise, and we obtain the smoothed image (Fig. 4(b)). The smoothed image is segmented by the intensity threshold determined by Otsu's threshold selection method to segment research objects (Fig. 4(c)), and a border line algorithm detects many border lines (Fig. 4 (d)). A medical doctor will select an interesting border line.



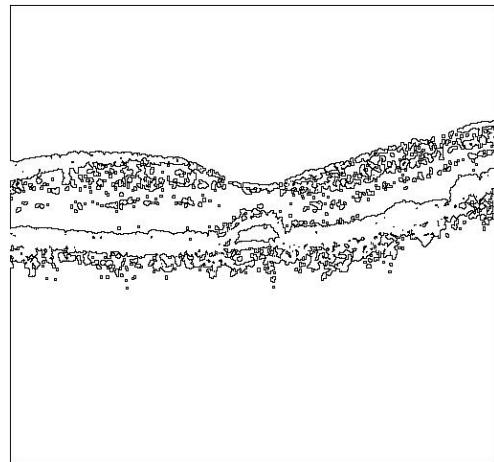
(a) An input OCT image



(b) Smoothed image

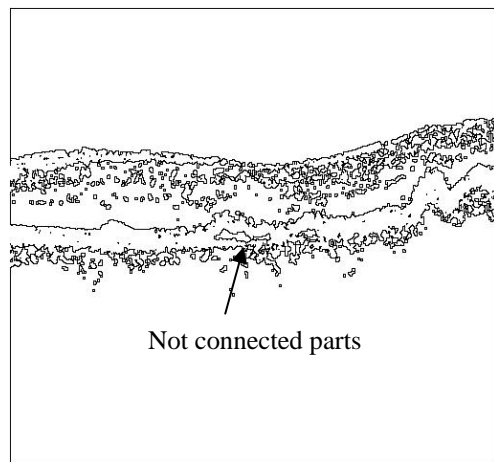


(c) Binary image

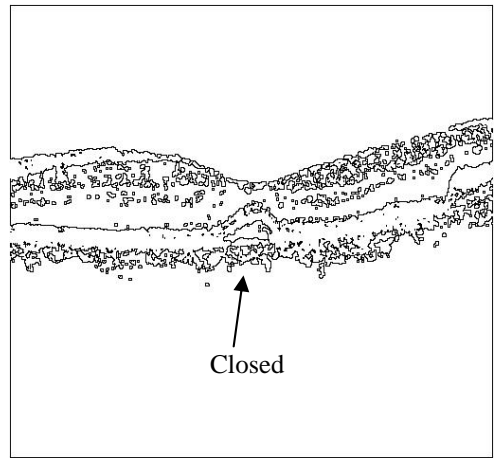


(d) Border line image

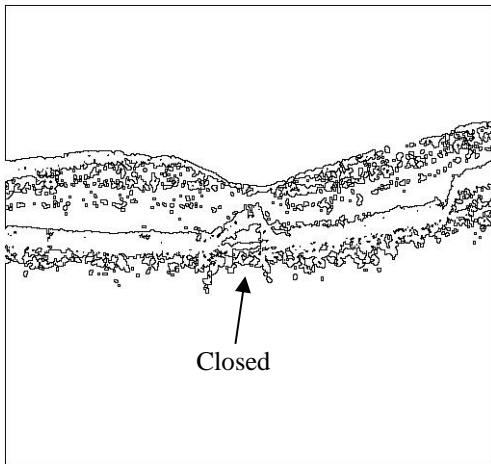
Fig. 4 The process images in our procedure



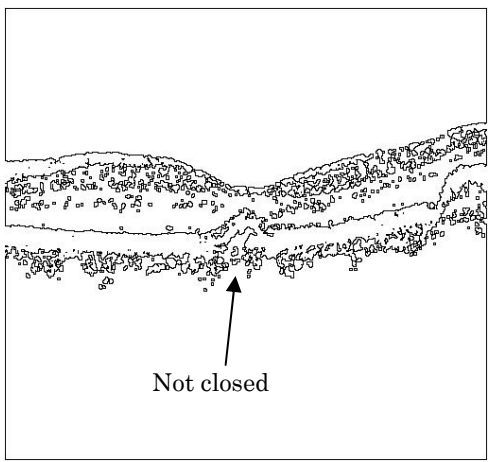
(a) Border line image before 5 slices of Fig. 4(d)



(b) Border line image after one slice of Fig. 4(d)



(c) Border line image after 2 slices of Fig. 4(d)



(d) Border line image after 5 slices of Fig. 4(d)  
Fig. 5 Some border line images for one eye

In the future the system could measure the area of an abnormal part on the OCT image, and it could measure the volume of the abnormal part using the adjoined OCT image in 3D connected binary images.

Fig. 5 shows the border line images of a series of OCT image for one eye. The border line of an abnormal part is closed on the some OCT images (Arrow line in Fig. 5 (b) and (c), and we can calculate the area of the abnormal part on these OCT images. However, on Fig. 5(a) the abnormal part divides to two pieces and on Fig. 5(d) the border line connected abnormal part is not closed. We cannot measure the area of border line. We are considering the connecting method on these images.

Presently, this research is researching cooperatively with ophthalmologist about various types of macular disease. We already implemented before the selection of an abnormal part using MS Visual C# language on Windows.

In the future, we will consider combining an analytical technology with the knowledge of ophthalmologists for the higher diagnosis performance.

#### IV. CONCLUSION

In this paper, we described a new extraction method for the abnormal regions of retina from 3D OCT images using the combination of digital image processing methods.

In the future, the following problems are important.

- (1) The connecting method for the border line of the abnormal part
- (2) The implementation of 3D display system about the surface of the abnormal part
- (3) The determination of the evaluation criteria for an abnormal part

#### REFERENCES

- [1] Huang D, Swanson EA. et al. Optical Coherence Tomography. *Science*, Vol.254: 1178-1181 (1991).
- [2] Drexler W, Morgner U, Ghanta RK, Kartner FX, Schuman JS, Fujimoto JG. Ultrahigh-resolution Ophthalmic Optical Coherence Tomography, *Nature Medicine*, vol7 no4:502-507 (2001).
- [3] Ko TH, Fujimoto JG, Schuman JS, Paunescu LA, Kowalevicz AM, Hartl I, Drexler W, Wollstein G, Ishikawa H, Duker JS. Comparison of Ultrahigh and Standard Resolution Optical Coherence Tomography for Imaging Macular Pathology, *Ophthalmology*;112:1922-1935(2005).
- [4] Hitzenberger CK, Trost P, Lo PW, Zhou Q. Three-dimensional Imaging of the Human Retina by High-Speed Optical Coherence Tomography, *Optics Express*, vol11, no21:2753-2761 (2003).
- [5] Ohno S, Kinoshita S. (ed). *Standard Ophthalmology*. Igaku-Shoin. (1981).
- [6] Yagi T, Okuyama F, Kawanaka H, Tsuruoka S. A Study On Extraction Method of Internal Limiting Membrane and Retinal Pigment Epithelium from OCT Images, *Proceeding of Joint 4<sup>th</sup> International Conference on Soft Computing and Intelligent Systems and 9<sup>th</sup> International Symposium on Advanced Intelligent Systems (SCIS&ISIS 2008)*, SU-G2-5:2008-2013 (2008).
- [7] Ai Yamakawa, Shinji Tsuruoka, Fumio Okuyama, Toshiki Yagi, "Automatic Extraction of Layer Structure for Retina in OCT Image Using Morphological Operation and Active Net, *Proc. of IAPR Conference on Machine Vision Applications (MVA2009)*, pp.42-45 (2009)