

# Effects of Intravitreal Aflibercept on Retinal Function and Improvement of Macular Edema Associated With Diabetic Retinopathy

Atsushi Ichio<sup>1</sup>, Masahiko Sugimoto<sup>1</sup>, Hisashi Matsubara<sup>1</sup>, Daiki Mochida<sup>2</sup>, Kumiko Kato<sup>1</sup>, and Mineo Kondo<sup>1</sup>

<sup>1</sup> Department of Ophthalmology, Mie University Graduate School of Medicine, Mie, Japan

<sup>2</sup> Mie University Graduate School of Medicine, Faculty of Medicine, Mie, Japan

**Correspondence:** Masahiko Sugimoto, Department of Ophthalmology, Mie University Graduate School of Medicine, 2-174 Edobashi, Tsu, 514-8507, Japan. e-mail: [sugmochi@clin.medic.mie-u.ac.jp](mailto:sugmochi@clin.medic.mie-u.ac.jp)

**Received:** May 29, 2020

**Accepted:** August 28, 2020

**Published:** October 6, 2020

**Keywords:** Anti-VEGF treatment; diabetic macular edema; electroretinography; micro aneurism; microperimetry

**Citation:** Ichio A, Sugimoto M, Matsubara H, Mochida D, Kato K, Kondo M. Effects of intravitreal aflibercept on retinal function and improvement of macular edema associated with diabetic retinopathy. *Trans Vis Sci Tech.* 2020;9(11):2. <https://doi.org/10.1167/tvst.9.11.2>

**Purpose:** To determine the effectiveness of intravitreal aflibercept (IVA) on the retinal function in eyes with diabetic macular edema (DME).

**Methods:** Twenty-five eyes of 25 patients with DME were treated with three consecutive monthly IVA injections. The retinal sensitivities (RS) within the central 10° were determined by microperimetry (MP). The central subfield macular thickness (CMT) was determined by optical coherence tomography, and the implicit times (IT) and amplitudes (Amp) of the flicker electroretinograms (ERGs) were determined from the ERGs elicited and recorded by the RETeval. The number of microaneurysms (MAs) was counted in the fundus photographs. The assessments were made before the IVA injections (pre-IVA) and one week after the IVA injections (post-IVA). The correlations between the reduction ratio of the MA numbers/CMT and RS/IT/Amp were evaluated.

**Results:** The mean RS improved from  $19.9 \pm 5.9$  dB to  $22.0 \pm 5.8$  dB, the CMT decreased from  $485.7 \pm 90.6$   $\mu$ m to  $376.9 \pm 81.6$   $\mu$ m, and the number of MAs decreased from  $49.6 \pm 33.2$  to  $24.8 \pm 18.1$  after the IVA injection (all  $P < 0.01$ ). The changes in the IT from  $31.3 \pm 3.3$  ms to  $31.5 \pm 3.1$  ms and the Amp from  $12.2 \pm 5.5$   $\mu$ V to  $11.3 \pm 6.1$   $\mu$ V post-IVA were not significant. A significant correlation was found between the relative changes in the CMT and RS ( $r = -0.43$ ;  $P = 0.02$ ), the MAs and RS ( $r = -0.38$ ;  $P = 0.03$ ). No significant correlation was observed between the relative changes of the number of MAs/CMT and IT/Amp.

**Conclusions:** IVA can improve both central retinal function and anatomical conformation.

**Translational Relevance:** A new aspect of aflibercept will be useful for DME treatment.

## Introduction

Diabetic retinopathy (DR) is a common and specific microvascular complication of diabetes and is a leading cause of preventable blindness in working-age individuals.<sup>1</sup> DR is associated with various microvasculature changes including the formation of microaneurysms (MAs) which are the most characteristic feature of DR.<sup>2,3</sup> Diabetic macular edema (DME) is a major complication of DR.<sup>4</sup> The presence of MAs is important because they are not only associated with the severity of the DR but also the cause of the DME. An

excessive leakage of plasma from the MAs results in a thickening of the retina which then damages the photoreceptors.<sup>5</sup> Histopathologic studies have demonstrated that MAs are small outpouching of the capillaries with focal endothelial cell proliferation,<sup>6</sup> and the loss of the barrier properties of the MAs cause the abnormal leakage resulting in DME.<sup>5</sup> The degree of such leakages can be detected by fluorescein angiography (FA), and MAs are identified as focal leakage points of hyperfluorescence.

Vascular endothelial growth factor (VEGF) is known to contribute to retinal ischemia and alterations of the microvasculature that cause DR and

DME. Pharmacologic therapies with anti-VEGF agents directly target the main cause of the DME, and they have become the first line treatment of DME.<sup>7,8</sup> Anti-VEGF agents have other properties that improve DR.

Mitchell et al. demonstrated a significant reduction in the progression of DR in eyes with DME eyes treated with aflibercept (Eylea, Regeneron Pharmaceuticals, Tarrytown, NY, USA),<sup>9</sup> and the DRCR.net protocol. S also reported that anti-VEGF agents were effective in treating proliferative diabetic retinopathy (PDR).<sup>10</sup> We have also shown that consecutive monthly intravitreal aflibercept (IVA) injections can reduce the number of MAs and peripheral retinal ischemia.<sup>11</sup> However, it is not still clear whether such improvements in the microvasculature will also affect the retinal function.

Microperimetry (MP) can be used to evaluate the physiological status of the central retina subjectively and quantitatively. MP measures the retinal sensitivity (RS) of the macular region within 10° of the fovea,<sup>12</sup> and it has been used to diagnose different types of macular disorders and to evaluate the effectiveness of different types of therapy.<sup>13–15</sup> Although there have been several studies that evaluated the central retinal function of eyes with DME,<sup>16–18</sup> none have evaluated the relationship between the RS and improvements of the DR.

Full-field electroretinography (ERG) can be used to determine the physiological status of the entire retina,<sup>19</sup> and it has been used to assess the status of the DR.<sup>20,21</sup> It has been found that the implicit times (ITs) and amplitudes (Amp) of the oscillatory potentials (OPs) were affected from the early stages of DR.<sup>22,23</sup> Other studies have shown that the ITs of the photopic b-waves and the 30-Hz flicker ERGs were strongly correlated with the severity of the DR.<sup>24–27</sup> However, there are disadvantages of conventional full-field ERGs, including the need to use a contact lens electrode, the long time to collect the data, and a large space needed for the pre-ERG dark-adaptation and recording. These disadvantages make it difficult for frequent examinations. Thus conventional full-field ERG recordings have not been used for screening a large population for DR and other eye diseases.

A new, small full-field ERG recording system called the RETeval system (RETeval: LKC Technologies, Gaithersburg, MD, USA) has been developed. The RETeval is a portable device that can record the flicker ERGs easily and quickly. The total recording time including the preparation is less than one minute. This device uses a single skin adhesive-tape electrode that can be attached to the lower eyelid without anesthesia. Previously, we have compared the ERGs recorded by the RETeval system with that recorded by the

conventional ERG system in normal volunteers. The amplitudes of the ERGs recorded with the RETeval were smaller because of the use of skin electrodes, but the ITs were not significantly different from that of the conventional ERG recording systems.<sup>28</sup> Similar findings have been reported for the ERGs recorded with skin and with corneal contact lens electrodes.<sup>29</sup> Thus we believe that the RETeval system is capable of assessing the physiological status of the retina. Thus the RETeval system has been used to evaluate the retinal function in normal subjects and individuals suspected of having a retinal disease.<sup>30–32</sup> We have reported that the IT and Amp of the flicker ERGs recorded by the RETeval system differed according to the severity of the DR.<sup>33</sup>

Although it is well known that anti-VEGF agents can improve the DME and DR, it has still not been definitively determined whether they can also improve the retinal function. Thus, the purpose of this study was to determine whether IVA injections will improve the retinal function both in the central retina and in the entire retina of the eye with DME. To accomplish this, we determined the central retina sensitivity by MP and the entire retina function by full-field and focal ERGs. We also evaluated the anatomical parameters including central subfield macular thickness (CMT) and the number of MAs to determine the status of the microvascular system.

## Patients and Methods

This prospective study was registered at <http://www.umin.ac.jp> (No. UMIN 000018315). Its protocol was approved by the Institutional Review Board of Mie University Hospital (No. 2913), and the procedures used conformed to the tenets of the Declaration of Helsinki. Oral and written consents were obtained from the patients after an explanation of the procedures to be used and possible complications.

## Demographics of Patients

The age, sex, level of creatinine, estimated glomerular filtration rate (eGFR), hemoglobin A1c (HbA1c), systolic/diastolic blood pressure (BP), and severity of the DR were determined at the baseline (pre-IVA) and at one week after the third IVA injection (post-IVA). All patients had a complete ophthalmologic examination that included measurements of the best-corrected visual acuity (BCVA), slit-lamp biomicroscopy, intraocular pressure measurements, indirect ophthalmoscopy, CMT measurements by spectral domain optical coherence tomography (SD-OCT),

RS determined by MP, flicker ERG recordings with the RETeval system, and FA.

The severity of the DR was classified into five groups: no DR, mild non-proliferative DR (mild NPDR), moderate NPDR, severe NPDR, and proliferative DR (PDR), according to the International Clinical Diabetic Retinopathy Severity Scale (DRSS).<sup>34</sup>

### Inclusion and Exclusion Criteria

All the patients were treatment naïve with anti-VEGF agents. Patients who had been diagnosed with DME and had received IVA without any additional treatment during the observation period were studied. The inclusion criteria were as follows: age >20 years, type I or II diabetes, BCVA  $\geq$ 20/320, DME involving the fovea, and a CMT >300  $\mu$ m measured as the mean retinal thickness in the central 1 mm diameter circle by SD-OCT.

The exclusion criteria were as follows: any retinal photocoagulation treatment in the studied eye within three months preceding the initial IVA, eyes with an ischemic macular region involving the fovea, eyes with vitreomacular traction, any history or presence of other ocular diseases causing vision reduction such as age-related macular degeneration and severe PDR, optic nerve atrophy, glaucoma or intraocular pressure >24 mm Hg, prior vitreous surgery, aphakia, anti-VEGF treatment of either eye within three months preceding the initial IVA, cloudy optic media including cataract through which high quality fundus photographs or SD-OCT images could not be obtained, history of cataract surgery in the studied eye within the previous three months, history of cerebrovascular accident, myocardial infarction or other systemic disease requiring medications that could affect the results, severe renal failure with creatinine >2.0 mg/dl or >Stage IIb of nephropathy defined by classification of diabetic nephropathy, poorly controlled hypertension with systolic BP >180 mm Hg or diastolic BP >110 mm Hg, poorly controlled diabetes mellitus with HbA1c >12.0%, and patients who were judged as ineligible for other reasons by the investigators.

### Microperimetry (MP)

The RS was measured by MP in a completely dark room with the Macular Integrity Assessment device (MAIA; Center Vue, Padova, Italy) after five minutes of dark adaptation. The examination was performed by the confocal-line scanning method under direct funduscopic observation with a field of  $36^\circ \times 36^\circ$  (resolution:  $1024 \times 1024$  pixels) and 25 Hz of tracking

speed. The RS was determined with the 4-2 strategy, and a target size of  $0.43^\circ$ , equivalent to Goldmann III, a luminance of 0.25 to 1000 asb (0.08 to  $318.3 \text{ cd/m}^2$ ), background luminance of 4 asb ( $1.27 \text{ cd/m}^2$ ), range of target luminance of 0 to 36 dB, and target presentation time of 0.2 s. The follow-up RS measurements were made at the same site using the high-speed eye tracking software. The average of the RS thresholds obtained at 37 points within the central  $10^\circ$  was defined as the average RS threshold.

### Full-Field Electroretinography (ERG)

Full-field flicker ERGs were recorded with the RETeval system as described.<sup>35</sup> After full mydriasis with topical 0.5% tropicamide and 0.5% phenylephrine HCl, (Mydrin-P; Santen Pharmaceutical Co., Ltd., Osaka, Japan), the flicker ERGs were recorded. A special skin electrode array (Sensor Strip; LKC Technologies, Inc., Gaithersburg, MD, USA) was placed 2 mm from the margin of the lower eyelid. This electrode array contained an active, a reference, and a ground electrode in a single adhesive tape. The electrical potentials were DC-amplified and digitized with a sampling rate of 2 kHz. The data resolution was 24 bits for 60.6 V, which is equal to approximately  $0.07 \mu\text{V}$ . The Amp and IT of the fundamental component were automatically measured and displayed by the RETeval system using a special algorithm with discrete Fourier transformation and cross-correlation analysis.

### Measurements of Best-Corrected Visual Acuity (BCVA)

The decimal BCVA was measured with a Landolt chart at every visit. The decimal BCVA was converted to the logarithm of the minimum angle of resolution (log MAR) units for the statistical analyses.

### Spectral Domain Optical Coherence Tomography (SD-OCT)

SD-OCT examinations were performed with the Spectralis OCT instrument (Heidelberg Engineering, Heidelberg, Germany). The structural OCT minimum acquisition protocol which included 19 horizontal raster linear B-scans with each composed of nine averaged OCT B-scans (1024 A-scans per line) covering an area of  $30^\circ \times 30^\circ$  was used. The CMT in the central 1-mm diameter circle of the Early Treatment Diabetic Retinopathy Study (ETDRS)

thickness map was determined by the Spectralis Software (Heidelberg Eye Explorer, version 1.9.11.0; Heidelberg Engineering, Germany).

### Intravitreal Injections

Each eye received 2 mg of IVA (40 mg/mL) under topical anesthesia. The injections were made with a 30-gauge needle that was inserted 4 mm posterior to the corneal limbus after paracentesis under sterile conditions. All patients received topical levofloxacin hydrate (1.5% Cravit ophthalmic solution) for three days after the injection. Each eye was treated with three consecutive monthly IVA injections.

### Fluorescein Angiography (FA)

FA was performed before the first IVA injection (pre-IVA) and after 3 consecutive monthly IVA injections (post-IVA). FA was performed with the Heidelberg Spectralis HRA+OCT module with a standard intravenous injection of 5 mL of 10% sodium fluorescein. The FA was performed before the initial IVA injection and after the loading phase. Images were obtained using the standard 35° field of view lens. One or more images during the early arteriovenous phase at 45 to 60 seconds was selected from each angiographic series. The images were transferred to the Adobe Photoshop ES software (Adobe Systems Inc, San Jose, CA, USA) or Image-J software (Image processing and analysis in JAVA1.46r, Wayne Rasband, National Institutes of Health, Bethesda, MD, USA). Hyperfluorescence pooling caused by leakages was considered to be a MA.

### Counting Number of MAs

The number of MA in the central area were counted as described.<sup>12</sup> The outer ring of the ETDRS circle of 6 mm centered on the fovea of the OCT thickness map was marked with the Photoshop program. These OCT images and the FA images obtained at the same time were merged. The hyperfluorescent dots in the area with retinal thickness >400 μm (color coded as red or warmer) were identified and counted as leakage points related to the DME. We compared the MA numbers at the pre-IVA with that at the post-IVA. All FA results were evaluated by three masked graders (AI, MS and DM). One evaluator counted each image three times, and the average value was used for the statistical analyses.

### Statistical Analyses

The results are presented as the means ± standard deviations. Paired *t*-tests were used to determine the significance of differences between two groups. To evaluate the relative changes between the number of MAs and the RS, IT, and Amp, we used d-values that are expressed as a reduction rates from the baseline values.

The d-values were defined as follow:

$$d - \text{values (\%)} = (\text{value post IVA} - \text{value pre IVA}) / \text{value pre IVA} \times (100).$$

Spearman's rank-order correlation coefficients were used to determine the significance of the correlations among the variables. The strength of the correlations (*r*-value) was classified as: 0.0 to 0.2 not correlated or very weak; 0.2 to 0.4, weak or low; 0.4 to 0.7, moderate; 0.7 to 0.9, strong or high; and 0.9 to 1.0, very strong. The  $\chi^2$  testing was used to determine the significance of the differences of the DRSS between the pre-IVA and after post-IVA. The results were considered statistically significant when  $P < 0.05$ .

## Results

Thirty eyes of 30 patients met the inclusion and exclusion criteria and were studied between September 2015 to March 2017 in the Department of Ophthalmology, Mie University Hospital. There were no IVA-related ocular complications including intraocular pressure elevations, infections, or any adverse systemic events. Five patients among the 30 patients could not complete the entire injection protocol or the entire examination schedule due to financial reason (three patients) or difficulty in transportation to the hospital (two patients).

### Baseline Characteristics

In the end, 25 eyes of 25 DME patients consisting of 14 men and 11 women were studied. Their mean age was  $64.0 \pm 8.8$  years. The average creatinine level was  $0.8 \pm 0.5$  mg/dL, the average eGFR was  $74.0 \pm 23.6$  mL/min/1.73 m<sup>2</sup>, average hemoglobin was  $14.0 \pm 2.2$  g/dL, and average HbA1c was  $7.8\% \pm 1.3\%$ . The average systolic BP was  $145.8 \pm 19.3$  mm Hg, and the average diastolic BP was  $72.4 \pm 13.0$  mm Hg.



**Table 1.** Demographics of Patients

	BCVA (logMAR Units)	CMT ( $\mu\text{m}$ )	MA	RS (dB)	IT (ms)	Amp ( $\mu\text{V}$ )
Pre-IVA	0.45 $\pm$ 0.35	485.7 $\pm$ 90.6	49.6 $\pm$ 33.2	19.9 $\pm$ 5.9	31.3 $\pm$ 3.3	12.2 $\pm$ 5.5
Post-IVA	0.40 $\pm$ 0.38*	376.9 $\pm$ 81.6**	24.8 $\pm$ 18.1**	22.0 $\pm$ 5.8**	31.5 $\pm$ 3.1	11.3 $\pm$ 6.1
<i>P</i> value	0.02	0.1 $\times$ 10 <sup>-6</sup>	0.3 $\times$ 10 <sup>-5</sup>	0.00007	0.40	0.33

Data are the means  $\pm$  standard deviations. \*  $P < 0.05$ , \*\*  $P < 0.01$  (paired *t*-test).

**Table 2.** Diabetic Retinopathy Severity Scale

	No DR	Mild NPDR	Moderate NPDR	Severe NPDR	PDR
Pre-IVA	0	0	12	13	0
Post-IVA	0	7	16	2	0

## Ocular Examination Findings

The mean baseline BCVA was 0.45  $\pm$  0.35 logMAR units, and the mean baseline CMT was 485.7  $\pm$  90.6  $\mu\text{m}$ . After the three consecutive monthly IVA, the mean BCVA was significantly improved to 0.40  $\pm$  0.38 logMAR units ( $P = 0.02$ , paired *t*-test, Table 1), and the mean CMT was significantly reduced to 376.9  $\pm$  81.6  $\mu\text{m}$  ( $P = 0.1 \times 10^{-6}$ , Table 1). The mean baseline number of MA was 49.6  $\pm$  33.2, and the mean number was significantly reduced to 24.8  $\pm$  18.1 in the post-IVA FA images ( $P = 0.3 \times 10^{-5}$ , Table 1).

The RS improved significantly from 19.9  $\pm$  5.9 dB at the baseline to 22.0  $\pm$  5.8 dB at the post-IVA examination ( $P = 0.00007$ , Table 1). The IT of the flicker ERGs changed from 31.3  $\pm$  3.3 ms at the pre-IVA to 31.5  $\pm$  3.1 ms ( $P = 0.40$ , Table 1) and the Amp changed from 12.2  $\pm$  5.5  $\mu\text{V}$  at the baseline to 11.3  $\pm$  6.1  $\mu\text{V}$  at the post-IVA. This change was not significant ( $P = 0.33$ , Table 1).

At the baseline, 12 eyes had moderate NPDR and 13 eyes had severe NPDR. After the IVA injections, 7 eyes had mild NPDR, 16 eyes had moderate NPDR, and 2 eyes had severe NPDR. Thus, the DRSS improved significantly ( $P = 0.002$ , Chi-square test, Table 2).

## Correlations Between d-Values of CMT and d-Values of RS, IT and Amp of the ERGs (Fig. 1)

A moderate significant correlation was found between the d-values of the CMT and the d-values of the RS ( $r = -0.43$ ,  $P = 0.02$ ; Spearman test, Fig. 1a). No significant correlation was found between the d-values of the CMT and the d-values of the IT ( $r = 0.27$ ,

$P = 0.20$ ; Fig. 1b), the d-values of the CMT and the d-values of the Amp ( $r = 0.03$ ,  $P = 0.88$ , Fig. 1c).

## Correlations Between d-Values of MA Numbers and d-Values of the RS, IT and Amp of the ERGs (Fig. 2)

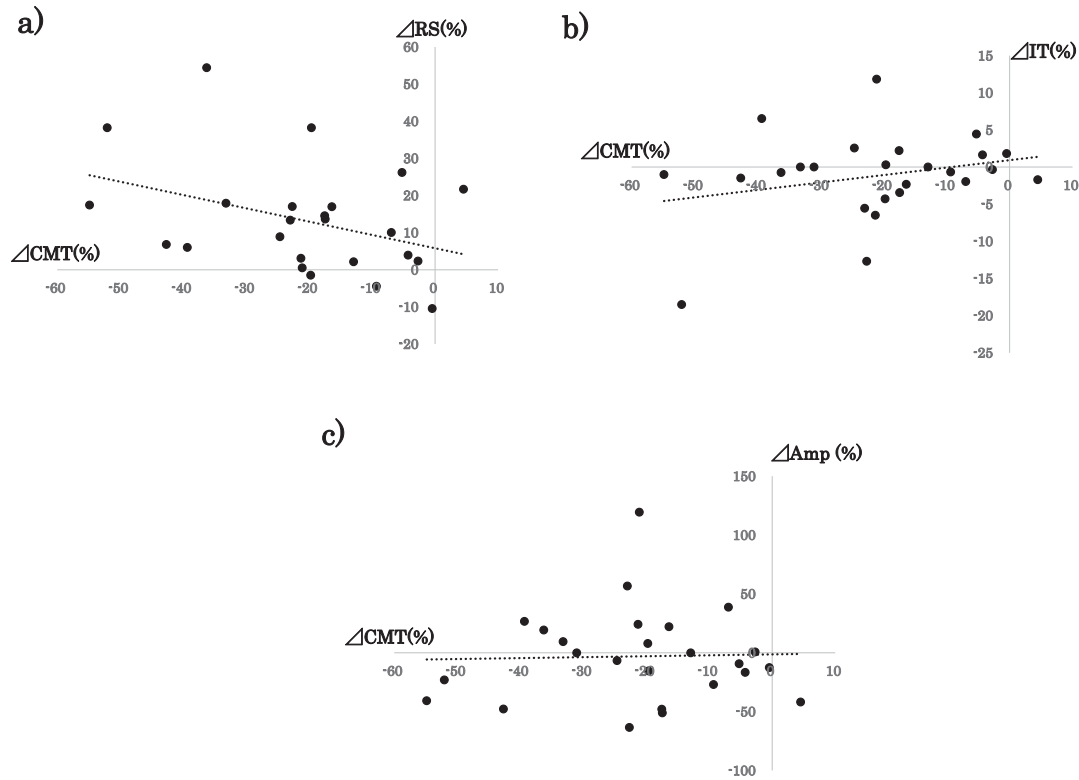
A significant correlation was found between the d-values of the MA and the d-values of the RS ( $r = -0.38$ ,  $P = 0.03$ ; Spearman test, Fig. 2a). No significant correlation was found between the d-values of the MA numbers and the d-values of the IT of the flicker ERGs ( $r = 0.11$ ,  $P = 0.60$ ; Fig. 2b), the d-values of the MA numbers and the d-values of the ERG Amps ( $r = 0.05$ ,  $P = 0.81$ , Fig. 2c).

## Case Presentation (Fig. 3)

The findings of a 53-year-old man who had DME with a CMT of 604  $\mu\text{m}$  in his right eye are presented in Figure 2. After three consecutive monthly IVA injections, the CMT was reduced to 465  $\mu\text{m}$ . The RS threshold before the treatment was 22.4 dB, which was markedly improved to 25.4 dB after the IVA treatment. The number of MAs evaluated by FA was also reduced from 72.7 to 21.7. The IT was 27.0 ms, and the Amp was 9.5  $\mu\text{V}$  before the injections. And, after the series of injections, these values did not change significantly (27.4 ms for the IT and 10.7  $\mu\text{V}$  for the Amp).

## Discussion

Our results showed that three consecutive monthly IVA injections improved the CMT and central RS significantly, but it did not significantly improve the IT and Amp of the full-field flicker ERGs. Although



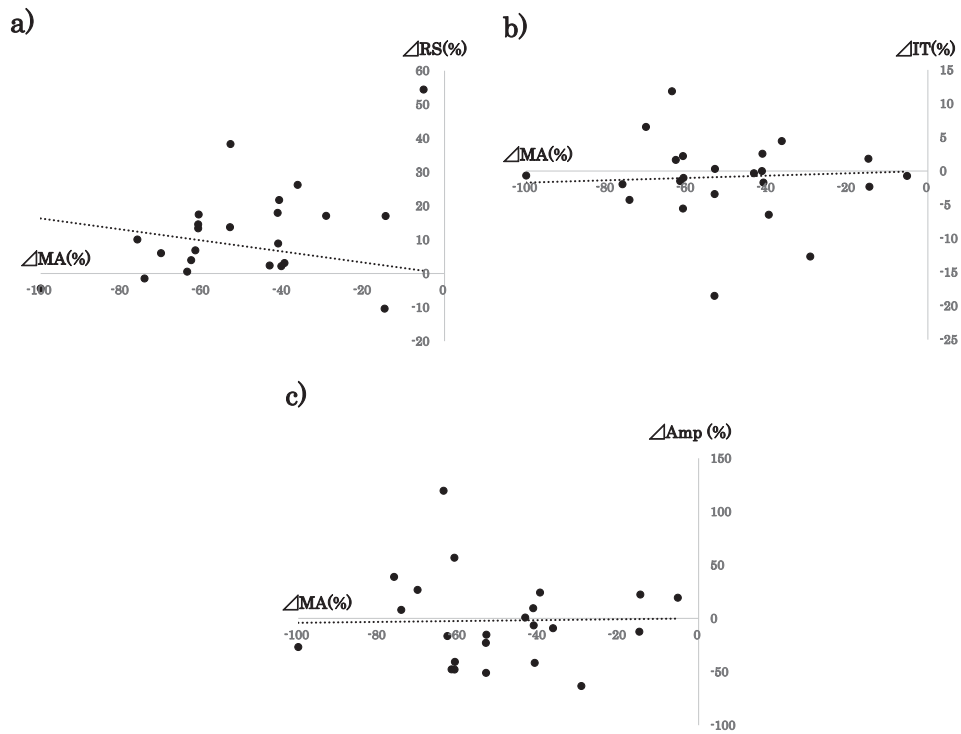
**Figure 1.** Correlation between the d-values of the central subfield macular thickness ( $\Delta CMT$ ), and the retinal sensitivity ( $\Delta RS$ )/implicit times ( $\Delta IT$ ) /amplitudes ( $\Delta Amp$ ). (a) Significant and moderate correlations were found between the d-values of the CMT ( $\Delta CMT$ ) and RS ( $\Delta RS$ ) ( $r = -0.43, P = 0.02$ , Spearman test). No significant correlation was observed for (b) the  $\Delta CMT$  and IT ( $\Delta IT$ ) ( $r = 0.27, P = 0.20$ ) or (c)  $\Delta CMT$  and Amp ( $\Delta Amp$ ) ( $r = 0.03, P = 0.88$ ).

the decimal BCVA improved significantly from 0.45 to 0.40, this change represented only an improvement of identifying a few more letters on the visual acuity chart. However, the central retinal sensitivity also improved significantly which indicates functional improvement. In addition, there was a significant reduction in the number of MAs and CMT which indicates the DR and DME improvement. These reductions were also significantly correlated with the degree of the central RS improvement. The strength of our study is that we evaluated not only the anatomical improvements (reduction in the number of MAs and the CMT) but also the functional status (improvement of the RS) of eyes with DME.

Our results confirm the results of earlier studies that also reported improvements of the RS after anti-VEGF treatments for eyes with DME.<sup>36,37</sup> Similar to MP, the multifocal ERGs (mfERGs) was also used to evaluate the central retinal function, and previous studies had reported that the mfERG findings demonstrated a retinal dysfunction in eyes with DME.<sup>38,39</sup> This dysfunction was significantly associated with the anatomic changes of the outer retina layer as a result

of neuroretinal alterations.<sup>38</sup> In addition, similar to our result, several studies have shown that the intravitreal injections of anti-VEGF agents can reduce not only the CMT but the number of MAs in eyes with DME.<sup>11,40,41</sup> Previously, we had reported that the CMT was significantly correlated with the number of MAs both before and after anti-VEGF treatments. A significant correlation was found between the CRT and number of MAs at both the baseline ( $r = 0.56$ ) and after treatment ( $r = 0.53$ ).<sup>11</sup> The reduction of the MAs was due to a direct effect of anti-VEGF agents on the retinal vessels, viz., a contraction or closure of the abnormal vessels, which was manifested as an improvement of the DR.<sup>42,43</sup> Our results showed that the correlation of d-values between anatomic improvements (CMT improvement and MA reduction), and the functional improvements (RS improvement), which indicate the new aspect of aflibercept.

Although we showed an improvement of the central retinal function, we did not find any improvement of the full-field ERG parameters which represents function of the entire retina. In addition, we did

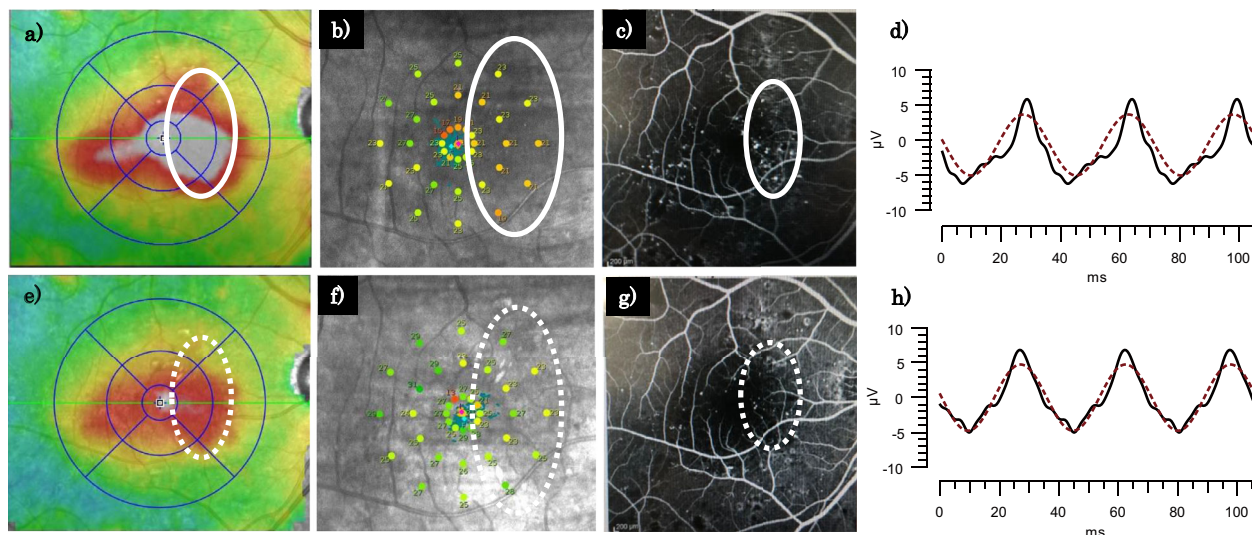


**Figure 2.** Correlation between the d-values of the microaneurysm numbers ( $\Delta MA$ ), and the retinal sensitivity ( $\Delta RS$ )/ implicit times ( $\Delta IT$ )/amplitudes ( $\Delta Amp$ ). (a) Significant correlations were found between the d-values of the MAs ( $\Delta MA$ ) and RS ( $\Delta RS$ ) ( $r = -0.38$ ,  $P = 0.03$ ; Spearman test). No significant correlation was observed for (b) the  $\Delta MA$  and IT ( $\Delta IT$ ), ( $r = 0.11$ ,  $P = 0.60$ ) or (c) the d-values of the MA and Amp ( $\Delta Amp$ ) ( $r = 0.05$ ,  $P = 0.81$ ).

not find any correlation between the d-values of the CMT or MA and d-values of the ERG components. Other study also reported no ERG changes over 48 weeks after ranibizumab injections for DME.<sup>36</sup> In contrast, there are some studies that reported improvements of the full-field ERGs after anti-VEGF treatment for DME. Holm et al. reported that the IT of the conventional 30 Hz full-field flicker ERGs was significantly shortened at 4 weeks after a ranibizumab injection for DME.<sup>43</sup> Terauchi et al.<sup>44</sup> reported that the IT of the full-field flicker ERGs recorded with the RETeval system was significantly shortened after the intravitreal anti-VEGF injections for various macular disease including DME although this was the result of a single injection and a short follow-up period. Yasuda et al.<sup>45</sup> reported improvements of the full-field ERG components after ranibizumab injection for the macular edema associated with a central retina vein occlusion (CRVO-ME) using the RETeval system. They concluded that ranibizumab can improve retinal function in eyes with CRVO-ME. But the ERG changes in eyes with DME are different from that of CRVO-ME because the ERG changes reflect damage of the entire retina from the chronic ischemia. On the other hand, the retinal damages in

eyes with CRVO-ME are the result of acute ischemia. The retinal damages of DR are associated with various complicated process, which results in retinal ischemia or fluid accumulation at the macula.<sup>46</sup> In fact, the severity of DR has been reported to be correlated with the full-field ERG parameters.<sup>33</sup> Thus there is a possibility that the entire retinal function was already damaged in DME for a long period, and its improvement may be slight even with the anti-VEGF treatment. The DRCR.net protocol-S study compared the visual field changes between a panretinal photocoagulation group and a ranibizumab treatment group. They reported there still remained mean peripheral visual field sensitivity loss in eyes treated with ranibizumab for five years. Because the ischemic mechanism of DR is complicated, it is still difficult to conclude whether anti-VEGF agents can improve the whole retinal function. We need more evaluations for this problem.

There are several limitations in this study. The main limitation was the small sample size and the short-term follow-up. Thus the interpretation of data should be made carefully. In addition, we did not evaluate the effect of other anti-VEGF agents including ranibizumab. A larger sample size and longer



**Figure 3.** Findings in a 53-year-old man who had DME with a CMT of 604  $\mu\text{m}$  in his right eye. Before treatment, the CMT was 604  $\mu\text{m}$  (a), the RS threshold was 22.4 dB (b), and the fluorescein angiogram show MA represented as high-intensity signals (c). Circles indicate same area in (a) to (c). Flicker ERG components determined from the ERGs recorded with the RETeval system and the IT was 27.0 ms, and the Amp was 9.5  $\mu\text{V}$  (d). After three consecutive monthly injections of aflibercept, a resolution of the DME was obtained with the CMT reduced to 465  $\mu\text{m}$  (e), and the RS improved to 25.4 dB (f). FA shows a reduction in the number of MAs (g). Dot circles indicate the same area in (e) to (g). Flicker ERG parameters were not changed significantly after the IVA injections (IT of 27.4 ms and Amp of 10.7  $\mu\text{V}$ ).

follow-up studies are needed to establish the benefit of anti-VEGF treatments. Second, only the fundamental component of the flicker ERG was analyzed, which is displayed automatically by the RETeval system. We need modifications to compare the fundamental component and raw waveform for a more effective analysis of the ERGs. Third, as shown in Figure 3, it appears that the improvement of the RS was most apparent in the nasal retina where the reduction in MAs was greatest. So, there may exist a spatial difference in the improvements of the RS. And finally, only the flicker ERG was evaluated, and scotopic ERGs were not recorded. This is because the repeated scotopic ERG recordings require at least 20 minutes of dark adaptation, which would be a burden on the patient. Further studies evaluating both the scotopic and photopic ERGs would be more informative. In spite of these limitations, we believe that the results are clinically important in that we could show the influence of the aflibercept on the central retina function consisted with CMT/MA regression and DR improvement.

reduction in the CMT and the number of MAs but also the central retina function in eyes with DME. This is a new aspect of aflibercept in that it can improve both the anatomic conformation and central retina function.

## Acknowledgments

The authors thank Emeritus Duco Hamasaki of the Bascom Palmer Eye Institute of the University of Miami for critical discussion and final manuscript revisions.

Presented at the 72<sup>nd</sup> Annual Congress of Japan Clinical Ophthalmology, October 2018 in Tokyo.

Disclosure: **A. Ichio**, None; **M. Sugimoto**, Alcon Pharma (F, C), Bayer (F, C), Kowa Pharma (C), Senju Pharma (C), Daiichi Yakuhin (C). Sangyo (C), Wakamoto Pharma (C); **H. Matsubara**, None; **D. Mochida**, None; **K. Kato**, None; **M. Kondo**, None

## Conclusions

In conclusion, our results showed that aflibercept can improve not only the DR as determined by the

## References

- Cheung N, Mitchell P, Wong TY. Diabetic retinopathy. *Lancet*. 2010;376:124–136.



2. Klein R, Meuer SM, Moss SE, Klein BE. (1995) Retinal microaneurysm counts and 10-year progression of diabetic retinopathy. *Arch Ophthalmol.* 1995;113:1386–1391.
3. Kohner EM, Stratton IM, Aldington SJ, Turner RC, Matthews DR. Microaneurysms in the development of diabetic retinopathy (UKPDS 42). UK Prospective Diabetes Study Group. *Diabetologia.* 1999;42:1107–1112.
4. Moss SE, Klein R, Klein BEK. The incidence of visual loss in a diabetic population. *Ophthalmology.* 1988;95:1340–1348.
5. The Diabetes Control and Complications Trial Research Group. Color photography vs fluorescein angiography in the detection of diabetic retinopathy in the diabetes control and complications trial. *Arch Ophthalmol.* 1987;105:1344–1351.
6. Flynn HW, Smiddy WE. *Diabetes and ocular disease*, San Francisco: The Foundation of the American Academy of Ophthalmology; 2000.
7. Diabetic Retinopathy Clinical Research Network. Randomized trial evaluating ranibizumab plus prompt or deferred laser or triamcinolone plus prompt laser for diabetic macular edema. *Ophthalmology.* 2010;117:1064–1077.
8. Brown DM, Schmidt-Erfurth U, Do DV, et al. Intravitreal aflibercept for diabetic macular edema: 100-week results from the VISTA and VIVID studies. *Ophthalmology.* 2015;122:2044–2052.
9. Mitchell P, McAllister I, Larsen M, et al. Evaluating the impact of intravitreal aflibercept on diabetic retinopathy progression in the VIVID-DME and VISTA-DME studies. *Ophthalmol Retina.* 2018;2:988–996.
10. Diabetic Retinopathy Clinical Research Network. Panretinal photocoagulation vs intravitreal ranibizumab for proliferative diabetic retinopathy: A randomized trial. *JAMA.* 2015;314:2137–2146.
11. Sugimoto M, Ichio A, Mochida D, et al. Multiple effects of intravitreal aflibercept on microvascular regression in eyes with diabetic macular edema. *Ophthalmol Retina.* 2019;3:1067–1075.
12. Laishram M, Srikanth K, Rajalakshmi AR, et al. Microperimetry—a new tool for assessing retinal sensitivity in macular diseases. *J Clin Diagn Res.* 2017;11:8–11.
13. Sjaarda RN, Frank DA, Glaser BM, et al. Assessment of vision in idiopathic macular holes with macular microperimetry using the scanning laser ophthalmoscope. *Ophthalmology.* 1993;100:1513–1518.
14. Midena E, Degli Angeli C, Blarzino MC, et al. Macular function impairment in eyes with early age-related macular degeneration. *Invest Ophthalmol Vis Sci.* 1997;38:469–477.
15. Ozdemir H, Karacorlu SA, Senturk F, et al. Assessment of macular function by microperimetry in unilateral resolved central serous chorioretinopathy. *Eye (Lond).* 2008;22:204–208.
16. Rohrschneider K, Bultmann S, Gluck R. Scanning laser ophthalmoscope fundus perimetry before and after laser photocoagulation for clinically significant diabetic macular edema. *Am J Ophthalmol.* 2000;129:27–32.
17. Midena E, Bini S. Multimodal retinal imaging of diabetic macular edema: toward new paradigms of pathophysiology. *Graefes Arch Clin Exp Ophthalmol.* 2016;254:1661–1668.
18. Vujosevic S, Torresin T, Berton M, et al. Diabetic macular edema with and without subfoveal neuroretinal detachment: two different morphologic and functional entities. *Am J Ophthalmol.* 2017;181:149–155.
19. McCulloch DL, et al. ISCEV Standard for full-field clinical electroretinography (2015 update). *Doc Ophthalmol.* 2015;130:1–12.
20. Tzekov R, Arden GB. The electroretinogram in diabetic retinopathy. *Surv Ophthalmol.* 1999;44:53–60.
21. Pescosolido N, Barbato A, Stefanucci A, Buomprisco G. Role of electrophysiology in the early diagnosis and follow-up of diabetic retinopathy. *J Diabetes Res.* 2015;2015:319692.
22. Yonemura D, Aoki T, Tsuzuki K. Electroretinogram in diabetic retinopathy. *Arch Ophthalmol.* 1962;68:19–24.
23. Simonsen SE. Electroretinography study of diabetics: a preliminary report. *Acta Ophthalmol. (Copenh).* 1965;43:841–843.
24. Bresnick GH, Palta M. Temporal aspects of the electroretinogram in diabetic retinopathy. *Arch Ophthalmol.* 1987;105:660–664.
25. Holopigian K, Seiple W, Lorenzo M, Carr R. A comparison of photopic and scotopic electroretinographic changes in early diabetic retinopathy. *Invest Ophthalmol Vis Sci.* 1992;33:2773–2780.
26. Tahara K, Matsuura T, Otori T. Diagnostic evaluation of diabetic retinopathy by 30-Hz flicker electroretinography. *Jpn J Ophthalmol.* 1993;37:204–210.
27. Satoh S, Iijima H, Imai M, et al. Photopic electroretinogram implicit time in diabetic retinopathy. *Jpn J Ophthalmol.* 1994;38:178–184.
28. Sugawara A, Kato K, Nagashima R, Matsubara H, Kondo M. Reproducibility of electroretinogram recorded by RETeval Complete in normal

- subjects [in Japanese]. *Folia Jpn Ophthalmol Clin.* 2017;10:289–294.
29. Bradshaw Keith, Hansen Ronald, Fulton Anne. Comparison of ERGs recorded with skin and corneal-contact electrodes in normal children and adults. *Doc Ophthalmol.* 2004;109:43–55.
  30. Kato K, Kondo M, Sugimoto M, et al. Effect of pupil size on flicker ERGs recorded with RETeval system: new mydriasis-free full-field ERG system. *Invest Ophthalmol Vis Sci.* 2015;56:3684–3690.
  31. Maa AY, Feuer WJ, Davis CQ, et al. A novel device for accurate and efficient testing for vision-threatening diabetic retinopathy. *J Diabetes Complications.* 2016;30:524–532.
  32. Miura G, Nakamura Y, Sato E, Yamamoto S. Effects of cataracts on flicker electroretinograms recorded with RETeval system: new mydriasis-free ERG device. *BMC Ophthalmol.* 2016;16:22.
  33. Fukuo M, Kondo M, Hirose A, et al. Screening for diabetic retinopathy using new mydriasis-free, full-field flicker ERG recording device. *Sci Rep.* 2016;6:36591.
  34. Wilkinson CP, Ferris FL, 3rd, Klein RE, et al. Global Diabetic Retinopathy Project Group. Proposed international clinical diabetic retinopathy and diabetic macular edema disease severity scales. *Ophthalmology.* 2003;110:1677–1682.
  35. Miyata R, Kondo M, Kato K, et al. Supernormal flicker ERGs in eyes with central retinal vein occlusion: clinical characteristics, prognosis, and effects of Anti-VEGF Agent. *Invest Ophthalmol Vis Sci.* 2018;59:5854–5861.
  36. Comyn O, Sivaprasad S, Peto T, et al. A randomized trial to assess functional and structural effects of ranibizumab versus laser in diabetic macular edema (the LUCIDATE study). *Am J Ophthalmol.* 2014;157:960–970.
  37. Gonzalez VH, Boyer DS, Schmidt-Erfurth U, et al. Microperimetric assessment of retinal sensitivity in eyes with diabetic macular edema from a phase 2 study of intravitreal aflibercept. *Retina.* 2015;35:687–694.
  38. Nagesh BN, Takkar B, Azad S, et al. Optical coherence tomography and multifocal electroretinography in diabetic macular edema: a neurovascular relation with vision. *Ophthalmic Surg Lasers Imaging Retina.* 2016;47:626–631.
  39. Goel N, Prakash A, Gupta AK. Multifocal electroretinography in diabetic retinopathy with and without macular edema. *Ophthalmic Surg Lasers Imaging Retina.* 2018;49:780–786.
  40. Cho HJ, Rhee TK, Kim HS, et al. Intravitreal bevacizumab for symptomatic retinal arterial macroaneurysm. *Am J Ophthalmol.* 2013;155:898–904.
  41. Leicht SF, Kernt M, Neubauer A, et al. Microaneurysm turnover in diabetic retinopathy assessed by automated RetmarkerDR image analysis—potential role as biomarker of response to ranibizumab treatment. *Ophthalmologica.* 2014;231:198–203.
  42. Schepcke L, Aguilar E, Gariano RF, et al. Retinal vascular permeability suppression by topical application of a novel VEGFR2/Src kinase inhibitor in mice and rabbits. *J Clin Invest.* 2008;118:2337–2346.
  43. Holm K, Schroeder M, Lövestam AM. Peripheral retinal function assessed with 30-Hz flicker seems to improve after treatment with Lucentis in patients with diabetic macular oedema. *Doc Ophthalmol.* 2015;131:43–51.
  44. Terauchi G, Shinoda K, Sakai H, et al. Retinal function determined by flicker ERGs before and soon after intravitreal injection of anti-VEGF agents. *BMC Ophthalmol.* 2019;19:129, doi:10.1186/s12886-019-1129-7.
  45. Yasuda S, Kachi S, Ueno S, et al. Flicker electroretinograms before and after intravitreal ranibizumab injection in eyes with central retinal vein occlusion. *Acta Ophthalmol.* 2015;293:465–468.
  46. Photocoagulation for Diabetic Macular Edema. Early Treatment Diabetic Retinopathy Study report number 1. Early Treatment Diabetic Retinopathy Study research group. *Arch Ophthalmol.* 1985;103:1796–1806.